
Case Report

Granulocytapheresis with Adacolumn in the Treatment of Four Patients with Intractable Ulcerative Colitis

Makoto Higuchi*¹, Akihiro Shinji*², Naoshi Nakamura*², Taiji Akamatsu*², Hideo Arakura*³, Toru Ichikawa*^{1, *3}, Kazuhiko Hora*^{1, *3}, Yuji Kamijo*¹, Yoko Kaneko*¹, Tetuji Kakegawa*¹ and Kendo Kiyosawa*²

*¹Nephrology Internal Medicine, *²Gastroenterology Internal Medicine, *³Division of Blood Purification, Shinshu University School of Medicine, Matsumoto, Nagano, Japan

Summary Four patients (3 men and 1 woman) with intractable ulcerative colitis (UC) were treated using granulocytapheresis (GCAP) with Adacolumn. Mean age at the first GCAP was 37.5 ± 11 years. Mean observation period before GCAP was 157 ± 105 months. A clinical activity index (CAI, Rachmilewitz criteria) and Matts' endoscopic classification were used for the estimation. GCAP was not effective in two cases, however it was very effective in the others. The CAI score of one male patient decreased from 8 to 5, and Matts' grade from 3 to 2, after the 5th GCAP. This patient could be taken off corticosteroid and the immunosuppressant. Then he received GCAP every month. Both his CAI score and Matts' grade had decreased to 1 sixteen months after the first GCAP. Four sessions of GCAP enabled us to reduce the prednisolone dose from 20 to 5 mg/day, and lowered the CAI score (8 to 4) of another male patient before total colectomy. Further examination is needed of the indications, times and intervals of GCAP in the treatment of intractable UC.

Key words: intractable ulcerative colitis, continuous granulocytapheresis, corticosteroid sparing, long morbidity period

In Japan, results from a multicenter clinical trial in patients with active UC provided the data on safety and efficacy required for the approval of Adacolumn (Japan Immunoresearch Laboratories, Takasaki, Japan) by the Japanese Ministry of Health, Labour, and Welfare (JMHLW) as a medical device for the treatment of active UC¹⁾. Adacolumn was approved by the JMHLW in April, 2000, and is available throughout Japan for treating active UC. However, indications, times and intervals of GCAP with Adacolumn in the treatment of patients with UC, have not been fully elucidated. We treated 4 long morbidity period patients (3 men and 1 woman) with intractable UC using GCAP and estimated the efficacy of the treatment with a clinical activity index (CAI, Rachmilewitz criteria) (Table 1) and Matts' endoscopic grade (Table 2)²⁾. We considered GCAP effective when the CAI score was less than 4 points or decreased more than 3 points. Among four patients, GCAP with Adacolumn was very effective in 2 male patients for reducing or stopping treatment with the cor-

ticosteroid and immunosuppressant.

Granulocytapheresis (GCAP)

GCAP was carried out with a 335-ml capacity column filled with 220 g of cellulose diacetate beads 2 mm in diameter as adsorptive carriers (Adacolumn). The carriers adsorb granulocytes and monocytes/macrophages. The column was placed in an extracorporeal setting. Venous blood was obtained continuously from 1 antecubital vein and passed through the column at a flow rate of 30ml/min with return to an antecubital vein on the contralateral arm. The duration of 1 adsorption session was 60 minutes. Each patient received 5 GCAP sessions (1 session/week) in principle as a basic treatment course³⁾.

Case report

Case 1: A 54 year old female was admitted to our hospital on May 22, 2000, for treatment of intractable UC. Fever, abdominal pain, and bloody stools had first appeared in 1975, and UC (total colitis type) was diagnosed. Administration of salazosulfapyridine (SASP) and prednisolone (PSL) ameliorated her symptoms.

3-1-1 Asahi, Matsumoto, Nagano 390-8621, Japan.
Tel: 0263-37-2823, Fax: 0263-37-3020

Table 1. Clinical activity index (CAI).

No of stools weekly	score	Abdominal pain/cramps	score
< 18	0	None	0
18–35	1	Mild	1
36–60	2	Moderate	2
> 60	3	Severe	3
Blood in stools (based on weekly average)		Temperature due to colitis (°C)	
None	0	37–38	0
Little	2	> 38	3
A lot	4	Extraintestinal manifestations	
Investigator's global assessment of symptomatic state		Iritis	3
Good	0	Erythema nodosum	3
Average	1	Arthritis	3
Poor	2	Laboratory findings	
Very poor	3	ESR > 50 mm/h	1
		ESR > 100 mm/h	2
		Hgb < 10 g/dl	4
Total score	0–31 points	(Rachmilewitz criteria)	

Table 2. Matts' endoscopic classification.

Grade	Degree	Findings
1	normal	a normal fine vascular pattern no easy mucosal bleeding
2	mild	loss of the normal fine vascular pattern no or mild easy mucosal bleeding no spontaneous mucosal bleeding mild mucosal redness, fine granular mucosa no abscess-like mucous
3	moderate	loss of the normal fine vascular pattern easy mucosal bleeding spontaneous mucosal bleeding edematous, reddish and coarse mucosa abscess-like mucous
4	severe	ulcer easy mucosal bleeding severe spontaneous mucosal bleeding abscess-like mucous extension disorder of large intestine

When the activity of her UC increased, additional administration of PSL improved her symptoms. Abdominal pain and bloody stools reappeared in March 2000. Administration of PSL and cyclosporine (CyA) did not reduce her symptoms. She was eventually diagnosed with total colitis, moderate, relapse-remitting type UC.

On admission, the PSL and CyA treatments were stopped and only SASP at 3 g/day continued to be administered. GCAP was started from May 30th, 2000. However, it was stopped because of high fever after 3 sessions. Though cultures of the nasopharynx, urine

and feces were negative, her fever disappeared five days after the administration of an antibiotic. Although the blood in her stools disappeared and the frequency of her stools decreased from June 2nd, 2000, the erythrocyte sedimentation rate (ESR) and C-reactive protein (CRP) level were unchanged after the third GCAP (Fig. 1). The CAI decreased from 19 to 17 points after GCAP, however, colonoscopic findings were unchanged (Matt's grade 3) (Fig. 5). In this case, it was very difficult to estimate the efficacy of GCAP, because GCAP had been performed only three times. Finally, she received a total colectomy in July, 2000.

Case 2: A 31 year old male was admitted to our hospital in July 2001. Mucous bloody stools had first appeared in 1993, and UC (left-sided colitis type) was diagnosed. Though administration of SASP alleviated his symptoms at first, blood reappeared in the stools and the frequency of stools continued to increase. Every time his UC relapsed, the administration of 20–30 mg/day of prednisolone improved his symptoms. He had a history of two admissions to hospital because of UC. He first came to our hospital in April, 2001. At that time, he was taking 40 mg/day of prednisolone, 100 mg/day of azathioprine (AZP) and 1.5 g/day of SASP orally. The dose of prednisolone was tapered 10 mg/day every two weeks. The dose of AZP was reduced to 50 mg/day from June 12th, 2001. Soon before he received the GCAP (from July 17th, 2001), PSL and AZP were stopped and the dose of SASP was increased from 1.5 g/day to 3.0 g/day. He was admitted to our hospital on July 19th, 2001. He received 5 sessions of GCAP, from July 23rd, every week. After the GCAP treatment, the frequency of stools decreased from 8 to 3 times per day, the abdominal pain disap-

GCAP) findings. Matts' grade was 1. His CAI score was 1 at that time. The interval between GCAP treatments was extended from 4 to 6 weeks from January 2003, the frequency of his stools increased from 1 to 3 times per day, bloody stools reappeared, and the CAI increased from 1 to 6 in the latter part of May. After receiving 5 sessions of GCAP (once per week) from the latter part of June, his symptoms decreased and his CAI

score became 1 again. Thereafter, GCAP was continued monthly for the treatment of his UC (Fig. 2).

Case 3: A 33 year old male was admitted to our hospital on November 30th, 2001 to receive GCAP. Bloody stools had first appeared in December 1995 and UC (total colitis type) was diagnosed. The administration of SASP ameliorated his symptoms; however the UC relapsed after a reduction in the dose of SASP. Admin-

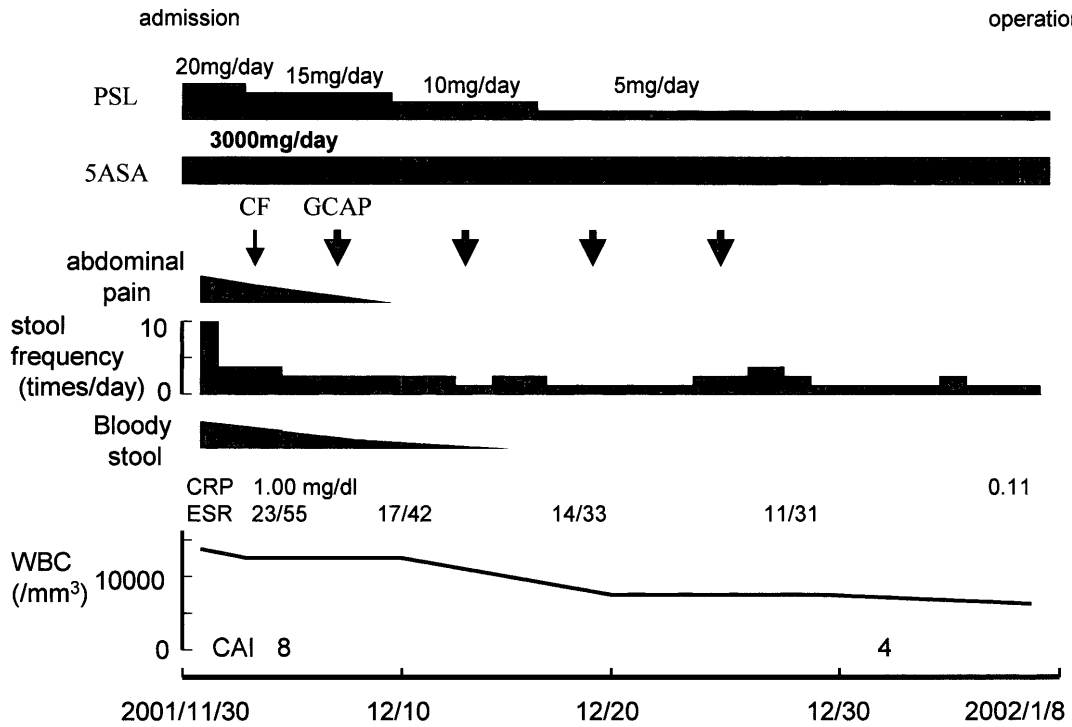


Fig. 3. Clinical course in Case 3.

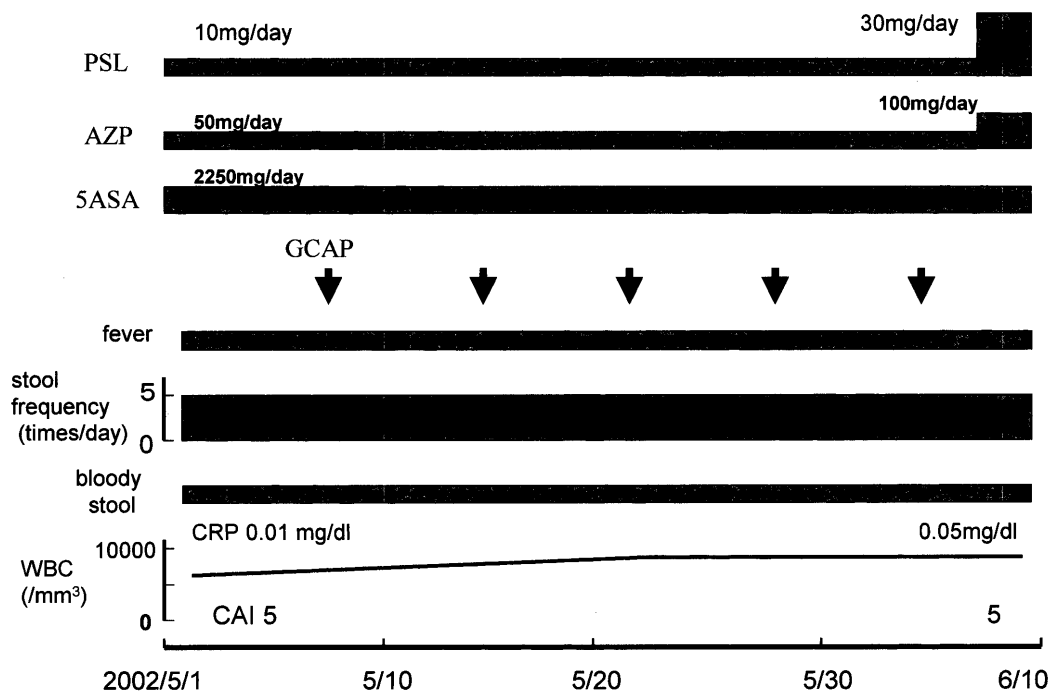


Fig. 4. Clinical course in Case 4.

istration of mesalazine (5ASA) instead of SASP did not improve his symptoms, and fever, abdominal pain and diarrhea reappeared. After receiving methyl-prednisolone pulse therapy, his symptoms finally subsided. As mucous bloody stools and their frequency increased after reducing the prednisolone dose, an additional administration of azathioprine was given, causing a remission of his UC. Mucous bloody stools and abdominal pain appeared again from February 2000. Increasing the dose of PSL improved his symptoms; however, his UC relapsed after the PSL dose was reduced. Four sessions of GCAP were scheduled for reducing the PSL dose and decreasing the activity of UC before total colectomy.

Though his PSL dose was decreased from 20 to 5 mg/day during the 4 GCAP treatments, the abdominal pain and bloody stools disappeared, the ESR improved, and the CAI score decreased from 8 to 4. He received a total colectomy on January 8th, 2002 (Fig. 3).

Case 4: A 33 year old male was introduced to our hospital in June, 1994. Diarrhea and bloody stools had first appeared in November 1991 and UC (left-sided colitis type) was diagnosed. Oral administration of prednisolone (50 mg/day) reduced the disease activity, however, his UC relapsed when the dose of PSL became 5 mg/day. Continuous SASP administration could not be performed because of an allergic effect. The dose of PSL was increased each time his UC relapsed.

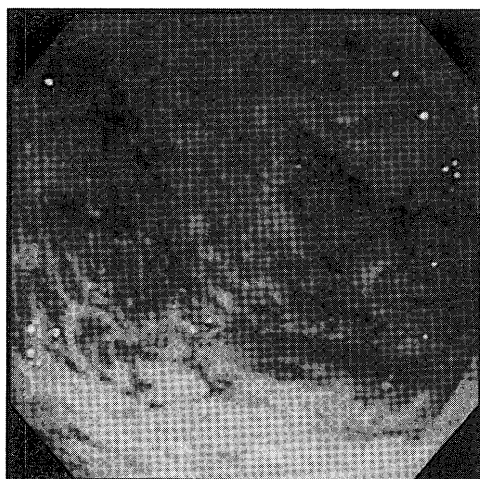
Five sessions of GCAP (once per week) were performed to reduce the PSL dose in out-patient care. However his CAI score (5) remained unchanged after the treatment. As GCAP was not effective, 30 mg/day of PSL, 100 mg/day of AZP, and 2,250 mg/day of 5ASA were administered after GCAP. These conventional treatments improved his symptoms (Fig. 4).

Table 3 gives a summary of the four UC patients who received GCAP. It was difficult to conclude

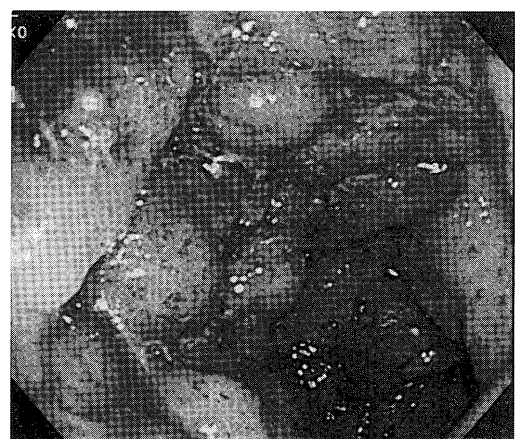
Table 3. Summary of 4 patients with UC

Case	Age Sex	Type	Duration (months)	trial sessions	pre CAI	post CAI	last CAI	Efficacy	outcome	pre-drug	post-drug
1	54 F	T, M, C	311	3	19	17		unknown	Ope.	PSL, CyA, SASP	5ASA
2	31 M	L, M, R	120	31	8	5	1	very effective		PSL, AZP, SASP	SASP
3	33 M	T, M, R	72	4	8	4		effective	Ope.	PSL, 5ASA	PSL, 5ASA
4	33 M	L, Mi, R	126	5	5	5		not effective		PSL, 5ASA	PSL, 5ASA AZP
Ave.	37.5		157.3								

Ave.: average, T: total colitis, L: left-sided colitis, M: moderate, Mi: mild, R: relapse-remitting, C: chronic continuous, CAI: clinical activity index, PSL: prednisolone, CyA: cyclosporine A, AZP: azathioprine, SASP: salazosufapyridine, 5ASA: mesalazine.



2000/5/23 (Matts 3)



2000/6/13 (Matts 3)

Fig. 5. Findings of colonoscopy in Case 1.

Left image shows the finding before GCAP. There were diffuse erosions, focal mucosal bleeding and focal ulcers. Right image shows the finding after 3 sessions of GCAP. There were focal deep ulcers.

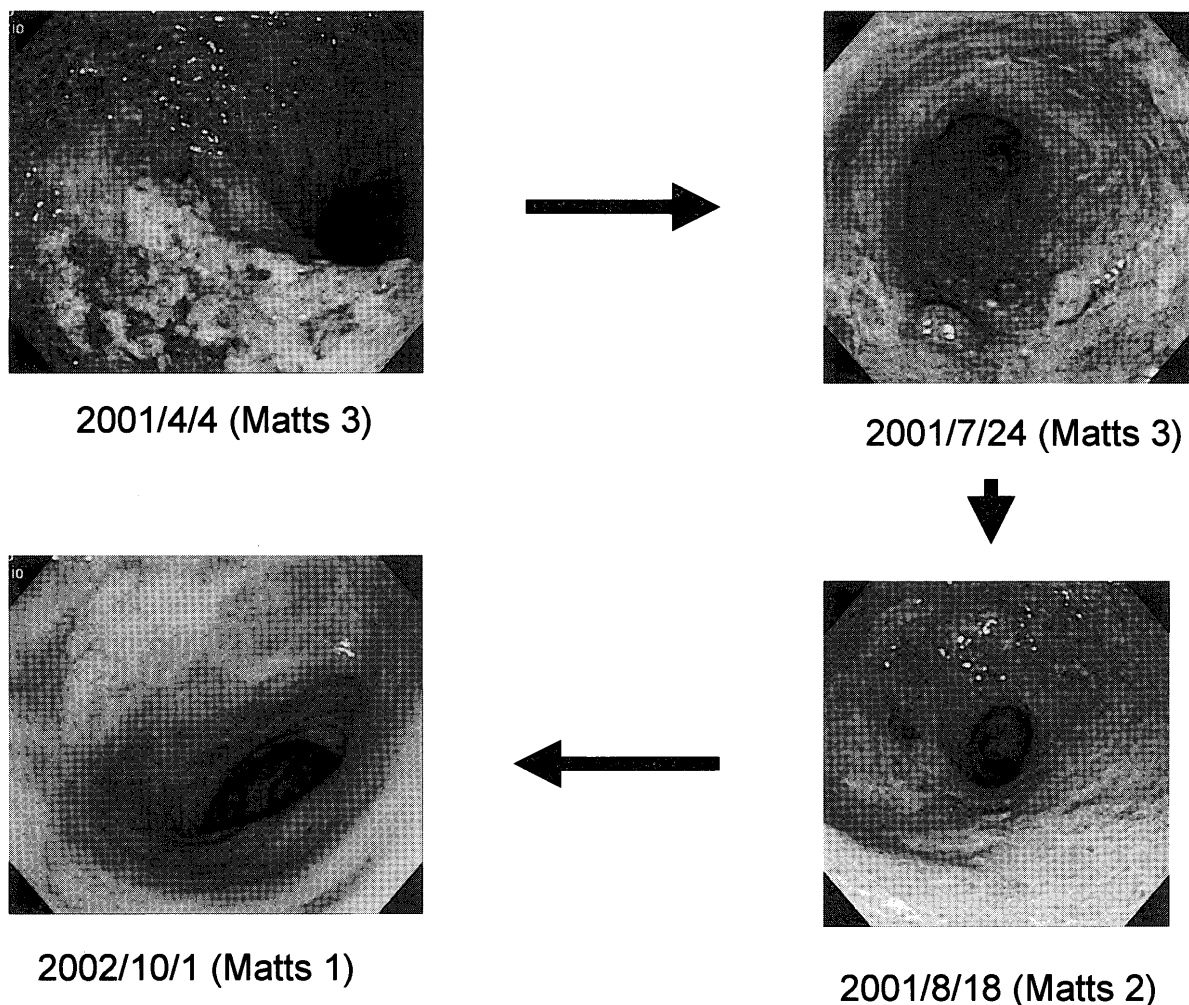


Fig. 6. Findings of colonoscopy in Case 2.

Left upper image shows the first finding in our hospital. There were multiple erosions, white coats, and shallow ulcers. Right upper image shows the finding one day after the first GCAP. There were still shallow ulcers. Right lower image shows the finding after the fifth GCAP. Mucosal epithelia were regenerated and a normal vascular pattern was seen in the mucosa. Left lower image shows the finding sixteen months after the first GCAP. Mucosal epithelia were regenerated and no ulcers were seen.

whether GCAP was effective or not in Case 1, because only three sessions were performed. GCAP was very effective in Case 2, because the use of PSL and the immunosuppressant could be stopped. Continuous GCAP treatment controlled the UC activity in Case 2, suggesting a new approach in GCAP treatment. GCAP was also effective in Case 3, because we could reduce the PSL dose and the CAI score decreased. GCAP was not effective in Case 4, because the CAI score was unchanged after the treatment.

Discussion

UC is recognized as a chronic, continuous, nonspecific inflammation of the colonic mucosa with a relapsing course. The etiology of UC is still unknown, therefore, it is difficult to cure this disease except with surgery. Circulating leukocytes activated by various chemical mediators in plasma, might be one of the etiologies of active UC⁴⁾. Recently, Adacolum which removes approxi-

mately 60% of monocytes and granulocytes semiselectively under flow conditions of 30 ml/min \times 60 min⁵⁾, was developed and officially approved for the treatment of severe and intractable UC in Japan. Shimoyama et al. suggested that the improvement achieved following GCAP may not be fully attributable to the removal of a fraction of granulocytes and monocytes; it might be partly attributed to immunomodulation via suppression of inflammatory cytokines and leukocyte trafficking⁶⁾. Moreover, Kashiwagi et al. reported immunomodulatory effects of GCAP as a treatment for patients with UC⁷⁾. Therefore, Shimoyama et al. suggested that good candidates for GCAP can be identified by a shortened morbidity period and endoscopic findings, such as an "erosive" type (which has diffuse edema, flare, and erosion) or an "ulcerated" type (which exhibits more marked edema, flare, and multiple but shallow ulcers). Moreover, they indicated that GCAP was not an adequate treatment for patients who have a long morbidity period

(more than 5 years) or show severe mucosal damage, such as pseudopolyposis or deep ulcerations (with severe mucosal defects, deep ulcers, or both)⁸⁾. The mean period before GCAP in our four patients was about 13 years, therefore, GCAP would be considered not to be very effective. However, it was very effective in Cases 2 and 3. A PSL sparing effect by GCAP was observed in Cases 3, even though the patient had suffered from UC for 6 years. In spite of long morbidity periods in Cases 2 and 3, there were no deep ulcers among colonoscopic findings before GCAP treatment, suggesting that the blood stream in the colonic mucosa might be preserved. Therefore, GCAP might be effective especially for UC patients with a long morbidity period who do not have severe mucosal damage, such as pseudopolyposis, deep ulcerations or both, as in Cases 2 and 3. Though medical insurance did not cover continuous GCAP treatment, the treatment was very effective in Case 2. Therefore, continuous GCAP treatment might be an effective alternative for intractable UC patients except for its high cost.

In Case 1, GCAP treatment was stopped because of high fever after 3 sessions. Though cultures of the nasopharynx, urine and feces were negative, her fever disappeared five days after the administration of an antibiotic. So bacterial infection might have occurred coincidentally during GCAP treatment. Therefore it was not clear whether the fever was a side effect of GCAP or not.

In Cases 4, 5 sessions of GCAP were not effective, suggesting that he had a long morbidity period and that his disease activity was not very high (CAI score was 5 before GCAP).

Except for the high fever in Case 1, there was no adverse effect of GCAP treatment among the 4 intractable UC patients.

Adverse effects of SASP, 5ASA, corticosteroids, and the immunosuppressant were a further problem in severe and intractable UC. In this regard, the continuous conventional GCAP would be an attractive treatment for severe and intractable UC except for its high cost.

Further examination is needed of the indications, times and intervals of GCAP in the treatment of patients with intractable UC.

References

- 1) Shimoyama T, Sawada K, Tanaka T, et al: Granulocyte and monocyte apheresis with the G-I column in the treatment of patients with active ulcerative colitis. *Jpn J Apheresis* **18**(1): 117-131, 1999 (in Japanese)
- 2) Matts SGF: The value of rectal biopsy in the diagnosis of ulcerative colitis. *Q J Med* **120**: 393-407, 1961
- 3) Hanai H, Watanabe F, Takeuchi K, et al: Leukocyte adsorptive apheresis for the treatment of active ulcerative colitis: a prospective, uncontrolled, pilot study. *Clin Gastroenterol Hepatol* **1**: 28-35, 2003
- 4) Panes J, Granger DN: Leukocyte-endothelial cell interactions: molecular mechanism and implications in gastrointestinal disease. *Gastroenterology* **114**: 1066-1090, 1998
- 5) Ohara M, Saniabadi AR, Kokuma S, et al: Granulocytapheresis in the treatment of patients with rheumatoid arthritis. *Artif Organs* **21**: 989-994, 1997
- 6) Shimoyama T, Sawada K, Hiwataishi N, et al: Safety and efficacy of granulocyte and monocyte adsorption apheresis in patients with active ulcerative colitis: a multicenter study. *J Clin Apheresis* **16**(1): 1-9, 2001
- 7) Kashiwagi N, Sugimura K, Koiwai H, et al: Immunomodulatory effects of granulocyte and monocyte adsorption apheresis as a treatment for patients with ulcerative colitis. *Digest Dis Sci* **47**(6): 1334-1341, 2002
- 8) Fukunaga K, Fukuda Y, Sawada K, et al: Poorly controlled ulcerative colitis treated by colectomy during remission induced by extracorporeal leukocyte removal therapy. *J Gastroenterol* **38**: 684-689, 2003