

## A Case Suspected Crossed Fused Renal Ectopia

Akira Uchino, Makoto Tanaka and Haruo Kuwano

Department of Radiology, Kyushu Welfare Pension Hospital, 2-1-1, Kishinoura,  
Yahatanishi-ku, Kitakyushu, 806, Japan

---

Research Code No.: 518.4

---

Key Words: Solitary kidney, Renal ectopia, Fused kidney,  
Single ureter, Angiography

---

### 交叉性癒合性腎変位と考えられる1例

九州厚生年金病院放射線科

内野 晃 田中 誠 栗野 晴夫

(昭和58年3月10日受付)

(昭和58年4月25日最終原稿受付)

交叉性癒合性腎変位は通常2個の腎盂・尿管を有するが、単一のものも稀ながら知られている。我々は血管造影にて本症と考えられる単腎症の1例を経験したので報告する。

症例は23歳の男性で、肉眼的血尿を主訴に来院した。右腎に結石と水腎症がみられた。血管造影

にて左腎はみられず、右腎は特異な形態を呈し、その下極は左総腸骨動脈起始部から分岐する動脈によって栄養されていた。逆行性腎盂造影では尿管が1本であったが、動脈造影所見から、左腎の無形成よりも交叉性癒合性腎変位 (unilateral fused kidney, inferior ectopia) と考えた。

### Introduction

Crossed fused renal ectopia (CFRE) is usually characterized by double renal pelves and ureters which drain into both sides of the urinary bladder. We experienced a case suspected CFRE with a single ureter, an unusual variety.

### Case Report

A 23-year-old man with painless macrohematuria was examined radiologically and urologically. Plain abdominal radiography revealed right renal calculi. Excretory urography showed a right hydronephrosis, but no left kidney (Fig. 1). Right retrograde pyelography revealed smooth narrowing at the right ureteropelvic junction (Fig. 2), but left ureteral orifice could not be visualized at cystoscopy.

Abdominal aortography demonstrated an anomalous right kidney and no left kidney (Fig. 3a, 3b). The right kidney was supplied by three feeding arteries, two of which arose from the abdominal aorta; the third; from the proximal end of the left common iliac artery (Fig. 3a, 4). Therefore, we diagnosed this case as crossed fused renal ectopia rather than unilateral renal agenesis.

No other congenital anomaly was found by physical and radiological examination.

Right pyeloplasty by dismembered Foley's method was performed for the right hydronephrosis. At

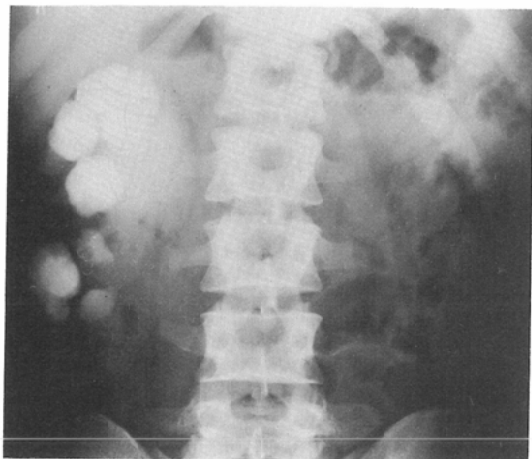


Fig. 1 Excretory urography showed a right hydronephrosis, but no left kidney. The right ureter was not identified.

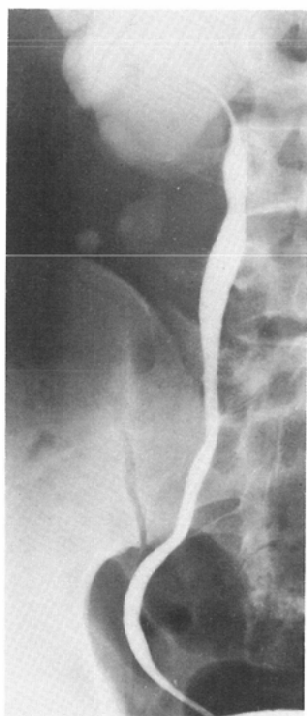


Fig. 2 Retrograde pyelography revealed stenosis at the right ureteropelvic junction. The left ureteral orifice could not be identified at cystoscopy.

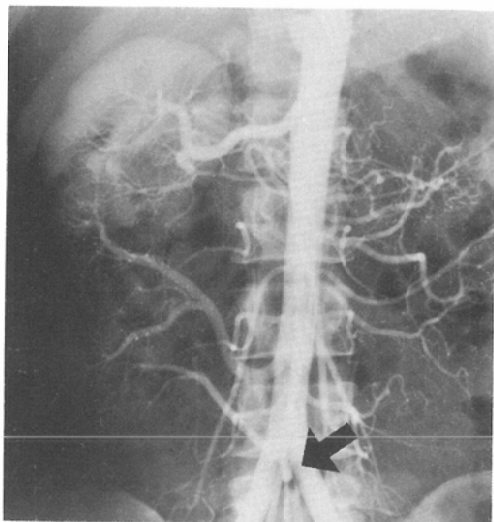


Fig. 3a Arterial phase of abdominal aortography. The right kidney has three feeding arteries, two of which arise from the abdominal aorta; the third, from the proximal end of the left common iliac artery (arrow). There is no left renal artery.

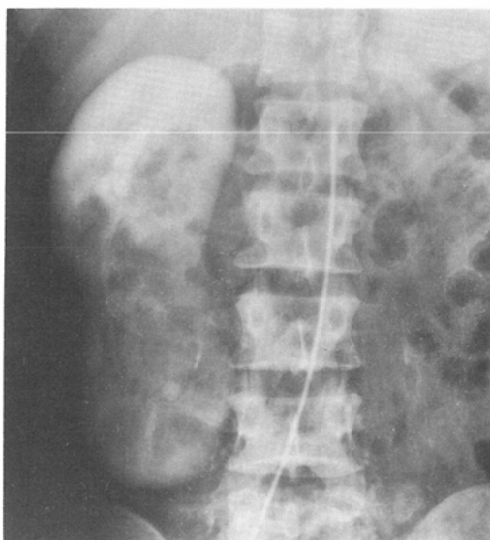

Fig. 3b Nephrogram phase of abdominal aortography demonstrated an anomalous right kidney and no left kidney.

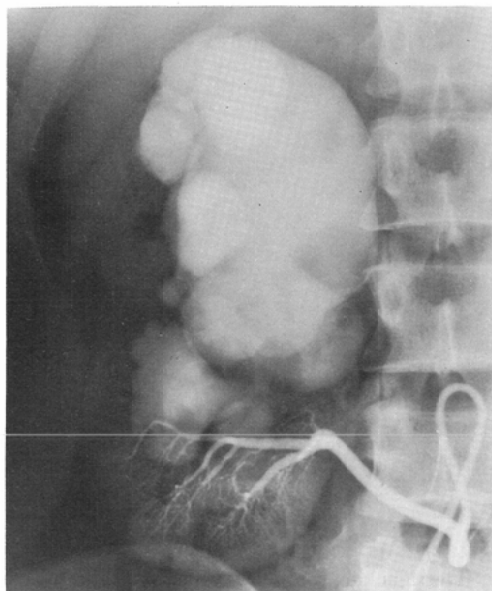


Fig. 4 The arterial phase of selective lower right renal arteriography shows that the lower pole of the right kidney is supplied by an artery arising from the proximal end of the left common iliac artery.

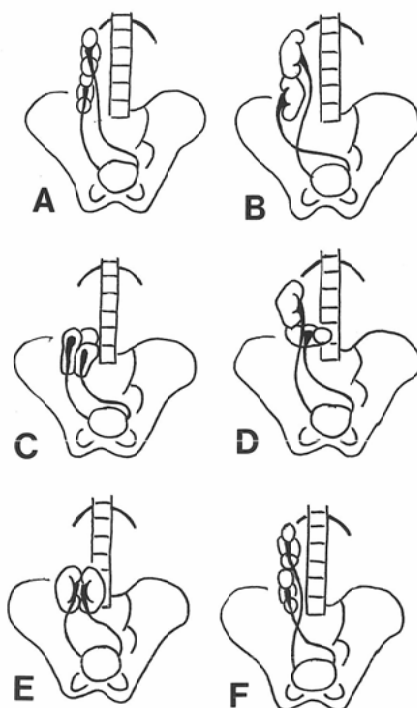


Fig. 5 Six varieties of CFRE<sup>4)</sup>. A, Unilateral fused kidney, superior ectopia. B, Sigmoid kidney. C, "Lump" kidney. D, L-shaped kidney. E, "Disk" kidney. F, Unilateral fused kidney, inferior ectopia.

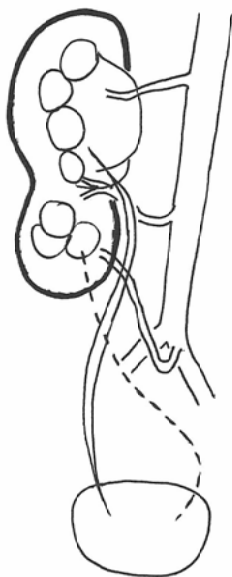


Fig. 6 Scheme of our case. Using McDonald and McClellan's classification<sup>4)</sup>, this case is "Unilateral fused kidney, inferior ectopia". However, crossed left ureter (dotted line) was not identified.

surgery, a single renal pelvis and a single ureter were identified.

### Discussion

Crossed fused renal ectopia (CFRE) is a relatively rare anomaly of the urinary tract. The incidence of this anomaly has been reported to be between 1 in 2,000 and 1 in 13,000 persons, with a predominance among males<sup>1)</sup>. Kyrayiannis et al.<sup>2)</sup> identified 5 cases of CFRE among 61 patients with renal ectopia. Cook and Stephens<sup>3)</sup> found 6 cases of CFRE in 41 persons with fused kidneys.

McDonald and McClellan<sup>4)</sup> illustrated 6 types of CFRE (Fig. 5). All cases of CFRE have double pelves and ureters which drain into both sides of the urinary bladder. However, CFRE has many variations<sup>5)</sup>. The present case had no left ureter. Daskalakis and Bouhoutsos<sup>6)</sup> reported a case of crossed renal ectopia without fusion, whose ectopic kidney was supplied by an artery which arose from the proximal end of the contralateral common iliac artery. In our case, the lower pole of the "right" kidney was supplied by an anomalous artery arising from the proximal end of the "left" common iliac artery. We, therefore, concluded that the upper pole of the crossed ectopic left kidney was fused with the lower pole of the normally situated right kidney. Using McDonald and McClellan's classification<sup>4)</sup>, our case is "Unilateral fused kidney, inferior ectopia" (Fig. 6).

To our knowledge, only one patient of CFRE with a single uncrossed ureter has been reported<sup>5)</sup>. Unilateral renal agenesis may be confused with this type of CFRE on excretory urography or retrograde pyelography, and arteriography is necessary to differentiate the two.

### Acknowledgment

We are grateful to Dr. Walter J. Russell and Dr. Tetsuo Omoto for their reviewing this manuscript.

### References

- 1) Campbell, M.F., Harrison, J.H.: Urology. 3rd Edition. pp. 1446—1455, 1970, W.B. Saunders, Philadelphia
  - 2) Kyrayiannis, B., Stenos, J., Deliveliotis, A.: Ectopic kidneys with and without fusion. *Br. J. Urol.* 51: 173—174, 1979
  - 3) Cook, W.A., Stephens, F.D.: Fused kidneys: Morphologic study and theory of embryogenesis. *Birth Defects* 13: 327—340, 1977
  - 4) McDonald, J.H. McClellan, D.S.: Crossed renal ectopia. *Am. J. Surg.* 93: 995—1002, 1957
  - 5) Witten, D.M., Myers, G.H. Jr., Utz, D.C.: Emmett's clinical urography. 4th Edition. pp. 593—619, 1977, W.B. Saunders, Philadelphia
  - 6) Daskalakis, E., Bouhoutsos, J.: Crossed renal ectopia without fusion: Case report with angiographic study. *Br. J. Surg.* 67: 142, 1980
-